Cruciate Ligament Removal Contributes To Abnormal Knee Motion During Posterior Stabilized Total Knee Arthroplasty

Melinda J. Cromie[1,4], Robert A. Siston[1,2,4,5], Nicholas J. Giori[3,4], Scott L. Delp[1,2,3,4]
Mechanical Engineering[1], Bioengineering[2], and Orthopaedic Surgery[3], Stanford University
Veterans Affairs Palo Alto Health Care System[4]
Mechanical Engineering and Orthopaedics, The Ohio State University[5]

Introduction

Total Knee Arthroplasty (TKA) is performed to relieve the pain of osteoarthritis. When posterior stabilized knee prostheses are implanted, the cruciate ligaments are removed and mechanical interaction between the femoral and tibial components is intended to stabilize the anterior-posterior motion of the knee. However, these implants result in abnormal anterior translation of the femur relative to the tibia[1,2,3]. This motion can lead to accelerated wear of the prosthesis and alter the moment arms of the muscles. The causes of this abnormal motion are unknown. We measured passive kinematics of the knee during surgery to answer two specific questions:

Does posterior cruciate ligament removal introduce abnormal anterior translation of the femur?

Does prosthesis implantation change the kinematics from the cruciate deficient case?

Methods

Figure 1. We measured the anterior-posterior translation of the knee throughout the range of flexion at four surgical stages using a surgical navigation system.

Intact
before removing the ligaments

No ACL
after removing the anterior cruciate ligament

No ACL No PCL
after removing the posterior cruciate ligament

TKA
after implanting the prosthesis

Results

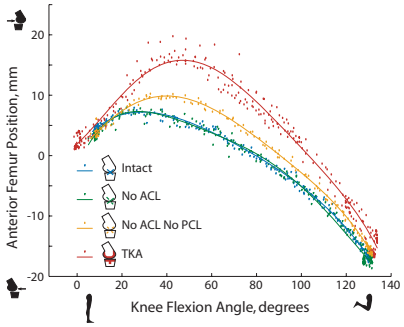

Figure 2. Anterior femur position throughout the range of flexion and extension for one subject at the four surgical stages. Experimental data represent three trials of flexion and extension. Data were fit with a fifth order polynomial. Mean RMS error was 0.8 mm.

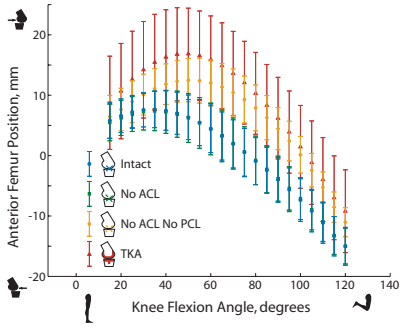

Figure 3. Anterior femur position throughout the range of knee flexion and extension for ten subjects at the four surgical stages. Mean ± SD.

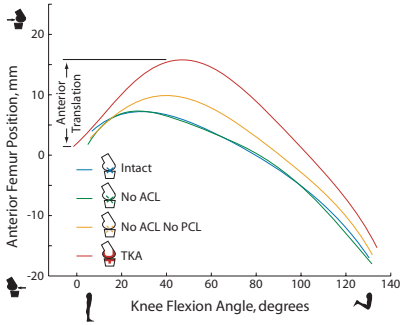

Figure 4. Anterior femur position throughout the range of knee flexion and extension for one subject at the four surgical stages. Arrow indicates anterior femur translation.

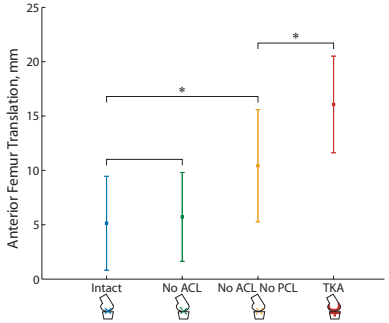

Figure 5. Anterior femur translation at the four surgical stages (mean ± SD). The mean anterior femur translation significantly increased with posterior cruciate ligament removal (No ACL No PCL) and with prosthesis implantation (TKA). *α=0.05

Discussion

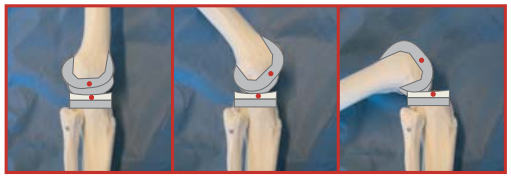

Figure 6. During early flexion, the femur moved anteriorly on the tibia. During deep flexion, the femur moved posteriorly on the tibia with normal femoral rollback. Red dots indicate the origins of the anatomic reference frames.

Conclusions

The abnormal anterior translation observed following posterior stabilized total knee arthroplasty was caused largely by removing the posterior cruciate ligament.

Normal motion was not restored by the posterior stabilized prosthesis.

References

1. Andriacchi et al. (2003) Clin Orthop Relat Res, 410, 44–53
2. Dennis et al. (2003) Clin Orthop Relat Res, 416, 37-57
3. Siston et al. (2006) J Orthop Res, 24, 1607-1614

Acknowledgements

NDSEG Fellowship